

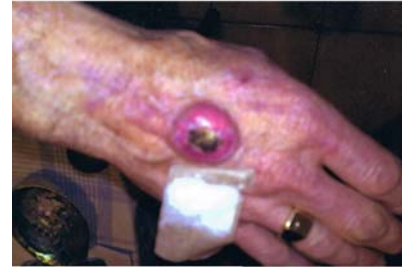Photo 1

## STRICTLY PRIVATE AND CONFIDENTIAL

### Patient Case Study Roger H3074

#### July 2007

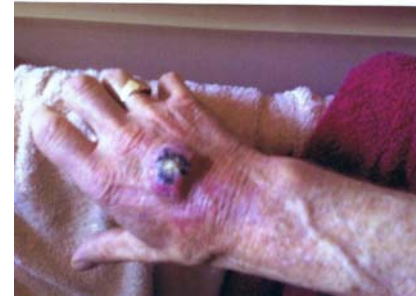Roger owns a specialised lubrication business supplying major companies manufacturing throughout Australia. He cut the back of his hand and, in Roger's words these are the events that followed. "I noticed a lump on the back of my hand, which was quite sore and would not heal. After visiting my doctor I was advised that it was an infection and a course of antibiotics was prescribed, however the lump continued to grow rapidly over the following two weeks" [photo 1].



#### August 2007

"Four weeks later I consulted a second medical opinion as the lump was now the size of a 50cent piece and raised-up like a carbuncle [photo 2] and the centre had a greenish/black growth gradually spreading over it. I was then given the news that I was suffering from a squamous cell cancer, already malignant at stage 3 and moving rapidly to stage 4. This was reinforced with his professional advice that if I did not undergo immediate surgery I could be dead by February 2008".

Photo 2



"Surgery would include cutting out the tumour and patching it with a skin graft from my buttock area. A friend of mine had recently experienced the same condition on his forehead and a similar operation had gone horrible wrong, so I looked for alternatives. By now the pain in my hand, arms and bones was bringing tears to my eyes and the greenish/black material in the tumour's centre had continued to spread [photo's 3 and 4]".

Photo 3

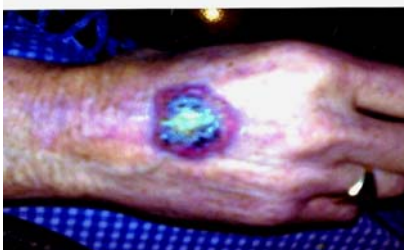
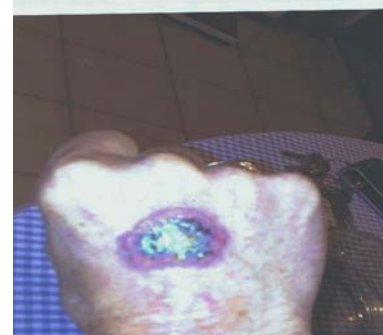
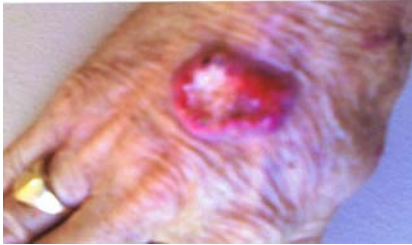
Photo 4



**September 2007**

“I then began researching alternative possible treatments and discovered Zeoactiv8 and commenced taking 80-90 drops per day. I had no time to wait. I took the ZeoActiv8 along with cellfood, spirulina and flax seed oil. Within four weeks after commencing, the tumour’s colour became bright red and the edges started to collapse and became flaccid where they were hard and extremely painfully before. [photo 5].”

Photo 5



**October 2007**

“During the first three weeks of October the centre of the tumour became filled with a whitish viscous fluid and the tumour resembled a small cherry pepper stuffed with fetta cheese. It gave off an unusual smell [photo 6 and 7]

Photo 6

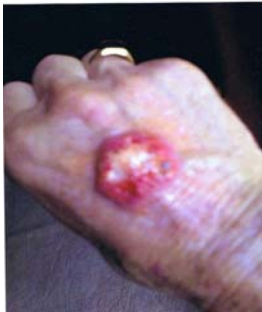
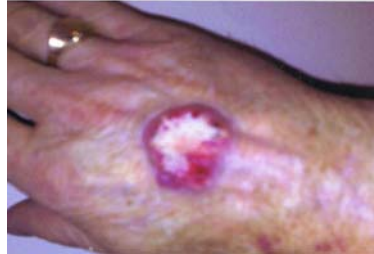
Photo 7



which was very similar to the smell of the ZeoAxtiv8. I found that the pain was lessening and I could write again, the redness of the tumour was fading and the hard edges began to soften further. [photo’s 8 and 9].”

Photo 8

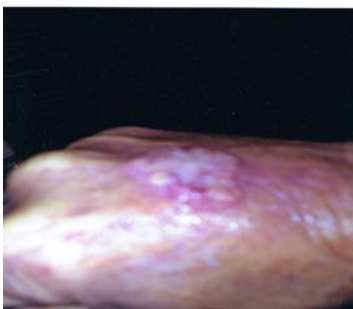
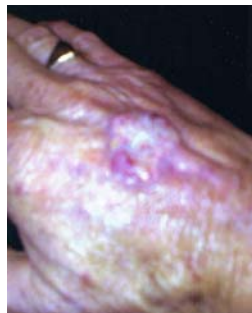
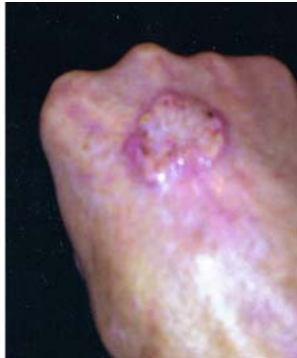

Photo 9



"In the fourth week the lump began to leak around the edges and become flaccid, eventually wobbling when I moved my hand [photo 10]. I could see the tumour in the middle of the soft surrounding tissue.

Photo 10



On the 27<sup>th</sup> of October, it was a Saturday, I broke it lose and actually lifted the tumour out of my flesh and put it on a piece of plastic [photo 11], leaving a gaping hole. There was no pain involved in removing the lump, though I did feel the sensation of 'threads' being stretched and snapped in the process. There was very little blood and I put an antiseptic on the wound and bandaged it."

Photo 11



"A surgeon advised me that the wound would never heal. I kept taking the ZeoActive8 but reduced the number of drops to 40. I then used Jade 168, 3 to 4 times a day, to rub into the wound. After 5 weeks the hole was almost completely closed over."

### **March 2008**

"It is now March 2008 and my body weight has improved from 47.4 Kg to 62Kg. My pre-condition weight was 67Kg. I have to look very closely now to identify where the tumour was and I have never felt better [photo 12]".

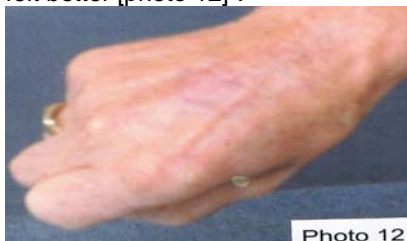

Photo 12

"The tumour I have stored in a glass jar in the freezer – safely out of harm's way".